

# The Effect of *Marrubium vulgare L.* on Hyperglycemia-Mediated Oxidative Damage in the Hepatic and Renal Tissues of Diabetic Rats

Zohra Ghilissi<sup>1\*</sup>, Rim Atheymen<sup>1</sup>, Zouheir Sahnoun<sup>1</sup>, Khaled Zeghal<sup>1</sup>,  
Hela Mnif<sup>2</sup> and Ahmed Hakim<sup>1</sup>

<sup>1</sup>Research unit of pharmacology and toxicology of xenobiotics (UR12 ES13),  
Faculty of Medicine, University of Sfax, 3029, Tunisia.

<sup>2</sup>Anatomopathology Laboratory, Habib Bourguiba University Hospital, 3029, Sfax, Tunisia.

## ABSTRACT

**Objective:** In the present study, we examined the antioxidant effect of *Marrubium vulgare L.* infusion (MVI) on renal and liver function in alloxan diabetic rats. **Material and methods:** Animals were divided into 4 groups: the control, treated rats with MVI (MVI), diabetic (Diab) and diabetic treated rats with MVI (Diab + MVI), for 30 days. Thereafter, blood samples were collected for the dosage of glucose, creatinine (Cr) and insulin level. The Kidney and liver were removed for the determination of oxidative stress markers [malondialdehyde (MDA), glutathione peroxidase (GPx), superoxide dismutase (SOD), catalase (Cat), reduced glutathione (GSH) and vitamins (E and C)] and histopathology examination. **Results:** Diabetic rats exhibited hyperglycemia, elevated of plasma Cr and insulin, oxidative stress markers impairment and renal and hepatic histological alteration. The treatment with MVI attenuates blood glucose, Cr and insulin level; reduced oxidative stress damage and improves histopathological alterations. **Conclusion:** The hypoglycemic effect and hepatorenal damage improvement of *M. vulgare* extract may be in part due to its antioxidant properties.

**Keywords:** Diabetes, hepatotoxicity, nephrotoxicity, *Marrubium vulgare L.*, antioxidants.

## INTRODUCTION

Diabetes mellitus (DM) is a chronic metabolic disorder, which not only impacts on human health and well-being, but also results in significant social and economic consequences. The incidence of DM throughout the world is increasing at an exponential rate such that the World Health Organization predicts that DM will be the seventh leading cause of death by the year 2030<sup>1</sup>.

Diabetic subjects also exhibit oxidative stress. Hyperglycemia has been found to play a key role in reactive oxygen species (ROS) generated damage<sup>2, 3</sup>. Oxygen free radicals, formed disproportionately in diabetes by glucose oxidation, non-enzymatic protein glycation and the subsequent oxidative degradation of glycated proteins<sup>3</sup>, may lead to several kinds of diabetic complications including nephropathy,

hepatotoxicity, neuropathy, cardiopathy and many others diseases.

The interest in plants with hypoglycemic properties has been renewed because of their perceived effectiveness, with minimal side effects and relatively low costs. *Marrubium vulgare Lamiaceae (M. vulgare L.)* is a perennial herb of the *Labiatae* family which is commonly known as "horehound" in Europe or "Marrubia" in Tunisia. The leaves and young flowering stems are used as antidiabetic, antiseptic, antispasmodic, diuretic, expectorant and tonic<sup>4</sup>. Several pharmacological properties traditionally ascribed to *M. vulgare* have been confirmed in laboratory studies such as: hypoglycemic<sup>5</sup>, antioxidant<sup>6</sup>, antihypertensive<sup>4</sup> and anti-inflammatory<sup>7</sup>. The hypoglycemic effect was demonstrated in alloxan-induced diabetic rats<sup>8, 9</sup>. However, there is no information available on

protective effect of *M. vulgare* against hepatotoxicity and nephropathy in diabetic rats. Therefore, this paper was designed to investigate whether the *M. vulgare* aqueous infusion could protect the liver and kidney from alloxan induced oxidative stress and histopathological alterations. Several studies have reported that there is a possibility of protective effect with *M. vulgare* treatment. However, no study is known about the nephro/hepato-protective effect of *M. vulgare* in either animals or humans.

## MATERIAL AND METHODS

### Plant preparation

*M. vulgare* L. was collected in June 2014 from the region of Sfax-Tunisia. The leaves were washed, dried at room temperature in the dark and then finely ground to a powder. The aqueous extract was prepared as follow: 6 g of the grounded *M. vulgare* were dissolved in 25 ml of boiling distilled water; the hot infusion was then left to reach room temperature (ca. 15 min) and filtered. The filtrate was given to rats<sup>9</sup>.

### Animals

Male *wistar* rats weighing  $250 \pm 10$  g were purchased from the breeding centre of the Central Pharmacy (SIPHAT). All animal procedures were conducted in strict conformity with the local Institute Ethical Committee Guidelines for the Care and Use of laboratory animals of our institution: they were kept in an environmentally controlled breeding room (temperature:  $22 \pm 2$  °C, humidity:  $60 \pm 5\%$ , 12 h dark/light cycle). All rats had free access to tap water and food.

### Experimental design

Experimental type 1 diabetes was induced in rats by a single intraperitoneal injection of freshly prepared alloxan solution in normal saline at 120 mg/kg b.wt<sup>10</sup>. As alloxan is capable of producing fatal hypoglycemia as a result of massive pancreatic insulin release, rats were orally treated with 20% glucose solution (5–10 ml) after 6 h. The rats were then kept for the next 24 h on 5% glucose water solution to prevent hypoglycemia. Rats with moderate diabetes that exhibited glycosuria and hyperglycemia (blood glucose concentration 200– 300 mg/dl) were taken for the experimental tests.

The rats were divided into three groups of 8 rats each as follows;

**Group 1:** Normal control rats received distilled water;

**Group 2:** Normal rats received 300 mg/kg b.w. of MVI;

**Group 3:** Diabetic rats received distilled water;

**Group 4:** Diabetic rats treated with 300 mg/kg b.w. of MVI.

The plant infusion was given to animal by oral gavage in twice daily for one month<sup>9</sup>.

### Preparation of blood, liver and kidney samples

At the end of treatment period, animals were anesthetized, sacrificed and blood samples were collected from the heart in heparin tubes and centrifuged at 2500 g for 15 min<sup>11, 12</sup>. The plasma was aliquoted into eppendorf tubes for determination of Cr level.

The kidneys and livers were removed, 500 mg of each organ were homogenized in 5 ml of lysis buffer (50 Mm Tris, 150 mM NaCl adjusted to pH 7.4) and centrifuged at 8000 g for 10 min<sup>13, 14</sup>. The supernatant was collected for the determination of MDA, SOD, CAT, GPx, GSH and vitamins (E and C) levels.

### Biochemical assays

#### **Estimation of uric acid and creatinine levels in plasma**

The levels of uric acid and creatinine in plasma were estimated spectrophotometrically using commercial diagnostic kits, respectively (Refs. 20143 and 20091) purchased from Biomagreb (Ariana, Tunisia).

#### **Estimation of glucose and insulin levels in plasma**

Glucose level in plasma was assayed by enzymatic methods, using the enzymatic colorimetric (GOD-PAP) glucose assay kit (Biomagreb, Tunisia) according to the manufacturer instruction. Plasma insulin was determined using rat insulin enzyme-linked immunosorbent assay (ELISA) kit Ref. RIT-461 No. AKRIN-010T (Shibayagi Co., Ltd., Japan).

#### **Protein quantification**

Protein contents in the kidney and liver were assayed by the method of Bradford (1976)<sup>15</sup>.

#### **Determination of Lipid peroxidation marker**

The MDA levels in renal and hepatic tissues were determined spectrophotometrically according to Draper and Hadley (1990)<sup>16</sup>.

### Determination of enzymatic antioxidants

The activities of SOD, CAT and GPx in renal and hepatic tissue were estimated according to Beauchamp and Fridovich (1971)<sup>17</sup>, Flohe and Gunzler (1984)<sup>18</sup> and Aebi (1984)<sup>19</sup>, respectively.

### Determination of non-enzymatic antioxidants

Glutathione (GSH) in tissue was determined by the method of Ellman (1959)<sup>20</sup> modified by Jollow et al. (1974)<sup>21</sup>. Ascorbic acid in the tissues was estimated by the method of Jacques-Silva (2001)<sup>22</sup>. Vitamin E was determined by the method of Baker et al. (1980)<sup>23</sup>.

### Histopathological examination

For light microscopic examination, kidney and liver removed from animals were cleaned and fixed in 10% buffered formalin solution. Then they were embedded in paraffin and stained with hematoxylin–eosin for histopathological studies. All sections were evaluated for the degree of tubular and glomerular injury and necrosis.

### Statistical analysis

Data are expressed as mean  $\pm$  SD (standard deviation). The statistical significance between experimental groups was assessed by one-way analysis of variance (ANOVA) followed by Tukey post-hoc test. Statistical significance was set at  $p < 0.05$ .

## RESULTS

### Variation of plasma creatinine level

Diabetic rats had significant elevated level ( $p < 0.001$ ) of plasma creatinine when compared with normal rats. Treatment with *M. vulgare* aqueous extract showed reversal of this parameter to near normalcy (table 1).

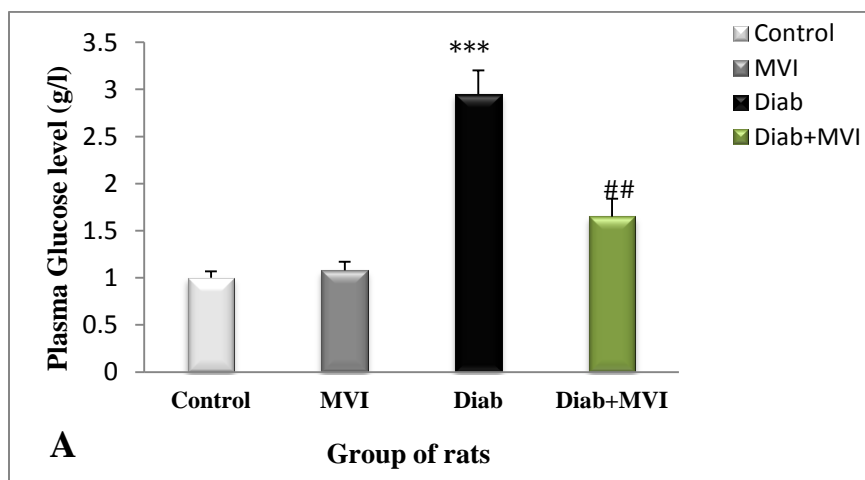
**Table 1:** Variation of plasma Cr level in the control, MVI, Diab and Diab + MVI experimental rats

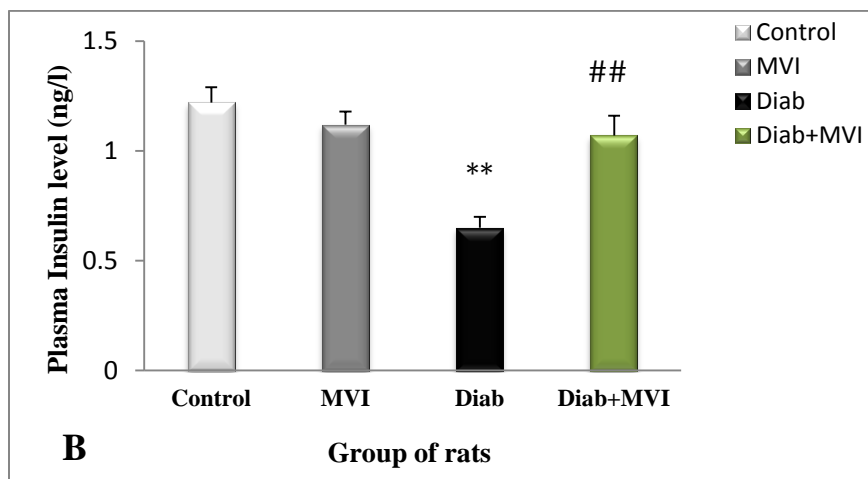
Group	Cr ( $\mu\text{mol/l}$ )
Control	112.76 $\pm$ 7.65
MVI	110.50 $\pm$ 6.58
Diab	175.85 $\pm$ 9.56 <sup>***</sup>
Diab + MVI	130.45 $\pm$ 8.47 <sup>##</sup>

Values are expressed as mean  $\pm$  SD of six rats. <sup>\*\*\*</sup> $p < 0.001$  vs. control; <sup>##</sup> $p < 0.01$  vs. Diab group. Cr: creatinine, MVI: *Marrubium vulgare* infusion, Diab: diabetic

### Variation of blood glucose and insulin levels

We showed a significant increase ( $p < 0.01$ ) in the level of blood glucose and a significant decrease ( $p < 0.01$ ) in plasma insulin of alloxan-diabetic rats, compared to normal group. Oral administration of *M. vulgare* aqueous extract to diabetic rats significantly decreased ( $p < 0.01$ ) the level of blood glucose and significantly increased ( $p < 0.01$ ) the level of plasma insulin, compared to diabetic rats (figure 1).





**Fig. 1:** Plasma glucose (mg/dl) (A) and insulin (B) levels in control rats (C), treated rats with *M. vulgare* infusion (MVI), diabetic rats (diab) and diabetic treated rats with *M. vulgare* infusion (Diab + MVI). Each value represents the mean  $\pm$  SE of six rats per group. \* $p < 0.05$  and \*\* $p < 0.01$  vs. control; # $p < 0.05$  vs. CMS group.

#### Variation of lipid peroxidative marker in the kidney and liver

The renal and hepatic tissues level of MDA increased significantly ( $p < 0.01$ ) in the diabetic group, compared to the control. The treatment with MVI attenuated tissular lipid peroxidation ( $p < 0.01$ ), compared to the diabetic group (Table 2).

#### Variation of enzymatic and non-enzymatic antioxidants activities in the kidney and liver

A significant decrease ( $p < 0.01$ ) in SOD, CAT and GPx activities was observed in the liver and kidney tissues of diabetic rats, compared with normal rats. Diabetic rats with MVI treatment showed a significant restoration of these antioxidant enzymes to near-normal values (Table 2). Similar results were found in non-enzymatic antioxidants; vit C, vit E and reduced glutathione (GSH) (Table 2).

**Table 2:** Variation of MDA level, enzymatic antioxidants (SOD, CAT and GPx) and non-enzymatic antioxidant (GSH, Vit E and Vit C) activities in the kidney and liver of the control, MVI, diab and diab + MVI experimental rats

	Control	MVI	Diab	Diab+ MVI
<b>MDA (nmoles/g)</b>				
Kidney	5.94 $\pm$ 0.79	5.60 $\pm$ 0.45	2.50 $\pm$ 0.15**	4.29 $\pm$ 0.36##
Liver	7.84 $\pm$ 1.05	6.90 $\pm$ 0.45	14.75 $\pm$ 2.65***	9.29 $\pm$ 1.12##
<b>SOD (U/mg protein)</b>				
Kidney	8.94 $\pm$ 1.12	7.80 $\pm$ 1.05	3.57 $\pm$ 0.55**	5.29 $\pm$ 0.35##
Liver	13.94 $\pm$ 1.21	12.32 $\pm$ 1.45	6.60 $\pm$ 0.63**	10.29 $\pm$ 1.16##

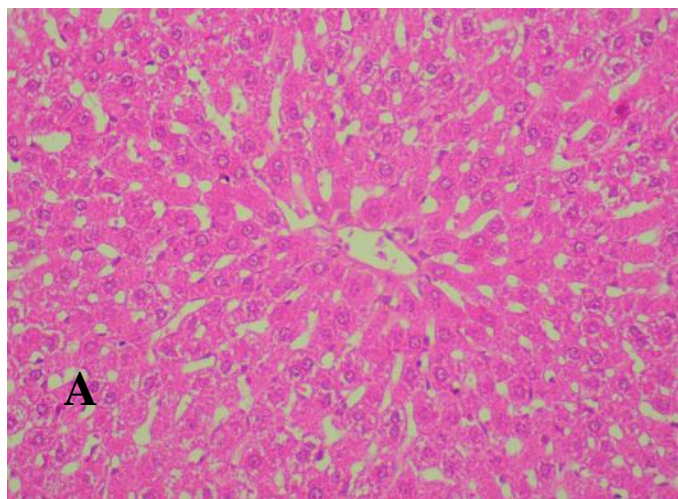
<b>CAT</b> (mmoles H <sub>2</sub> O <sub>2</sub> /mg protein)				
Kidney	4.54 ± 0.29	4.60 ± 0.45	2.32 ± 0.25 <sup>**</sup>	3.29 ± 0.18 <sup>##</sup>
Liver	6.84 ± 0.75	5.80 ± 0.58	3.80 ± 0.25 <sup>**</sup>	4.89 ± 0.56 <sup>##</sup>
<b>GPx</b> (nmol GSH/min/mg protein)				
Kidney	6.94 ± 0.89	6.65 ± 0.45	3.67 ± 0.65 <sup>**</sup>	5.19 ± 0.84 <sup>##</sup>
Liver	9.85 ± 1.57	9.50 ± 1.25	4.54 ± 0.65 <sup>***</sup>	7.29 ± 1.06 <sup>##</sup>
<b>GSH</b> (mg/g)				
Kidney	5.83 ± 0.895	5.60 ± 1.05	2.58 ± 0.23 <sup>**</sup>	4.29 ± 0.26 <sup>##</sup>
Liver	7.83 ± 1.09	7.60 ± 1.05+	3.35 ± 0.65 <sup>**</sup>	6.09 ± 0.71 <sup>##</sup>
<b>Vit E</b> (mg/mg protein)				
Kidney	3.84 ± 0.29	3.70 ± 0.1	1.65 ± 0.15 <sup>**</sup>	2.89 ± 0.16 <sup>##</sup>
Liver	6.94 ± 0.34	6.60 ± 0.45	3.25 ± 0.27 <sup>***</sup>	4.59 ± 0.26 <sup>##</sup>
<b>Vit C</b> (mg/g tissue)				
Kidney	185.94 ± 8.79	179.60 ± 8.45	119.35 ± 6.70 <sup>**</sup>	164.25 ± 7.16 <sup>##</sup>
Liver	225.24 ± 13.13	221.60 ± 12.45	171.65 ± 9.65 <sup>**</sup>	199.29 ± 9.16 <sup>##</sup>

Values are expressed as mean ± SD of six rats. \*p < 0.05, \*\*p < 0.01 and \*\*\*p < 0.001 vs. control; #p < 0.05, ##p < 0.01 and ###p < 0.001 vs. Diab group. MDA = Malondialdehyde, SOD = superoxide dismutase; Cat = catalase; GPx = glutathione peroxidase; GSH = reduced glutathione; Diab = diabetic; Vit = vitamin.

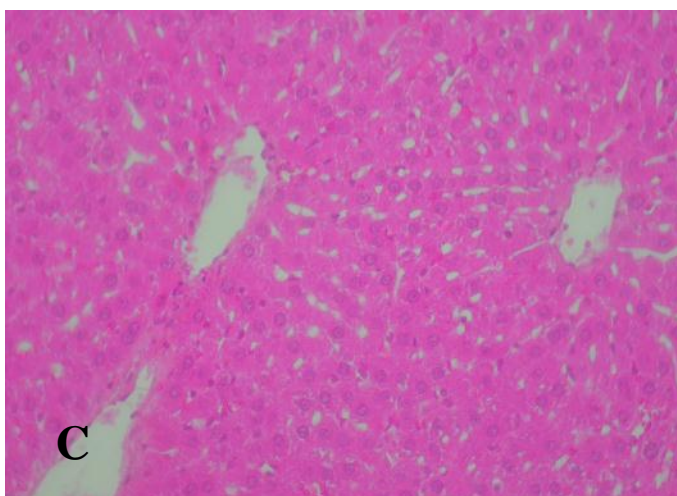
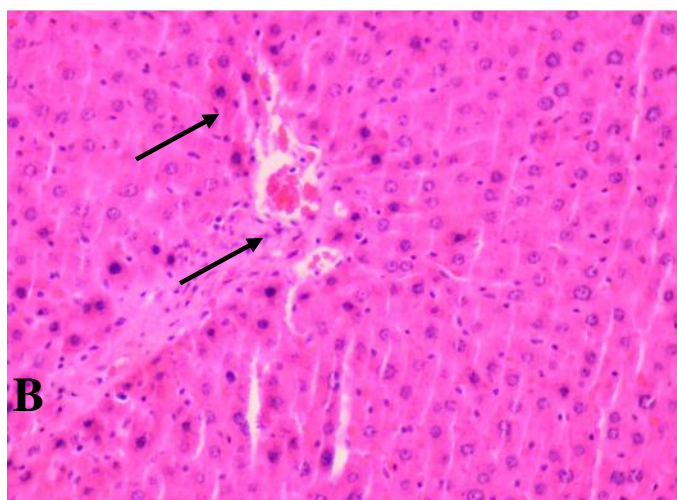
### Histopathological observations of Kidney and liver

The histological examination of liver tissue of control and treated rats with *M. vulgare* showed normal hepatocyte arrangement. However, the hepatic tissues of diabetic rats exhibited extensive damage with cells vacuolization and necrosis. The diabetic treated rats with *M. vulgare* infusion presenting normal hepatocyte arrangement (Fig. 3A–C).

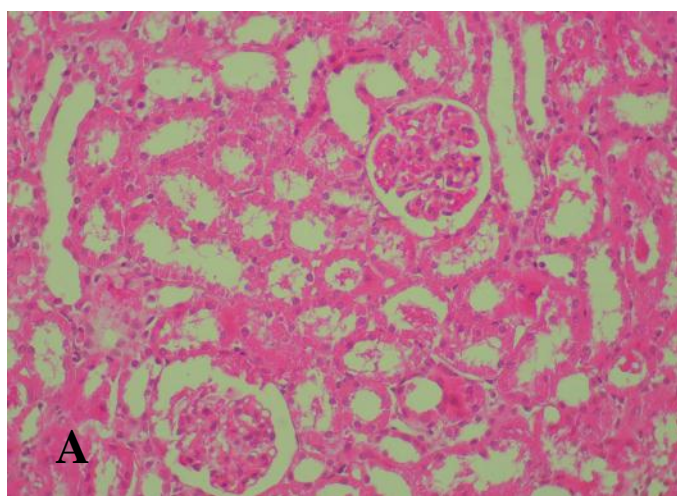
The section of kidney tissue of control and *M. vulgare* groups showed normal cells' architecture. However, the renal of diab rats elicited a significant morphological changes with severe injury of tubular and glomeruli. The diabetic treated rats with *M. vulgare* showed a glomeruli and tubules with no significant pathology (Fig. 4A–C).

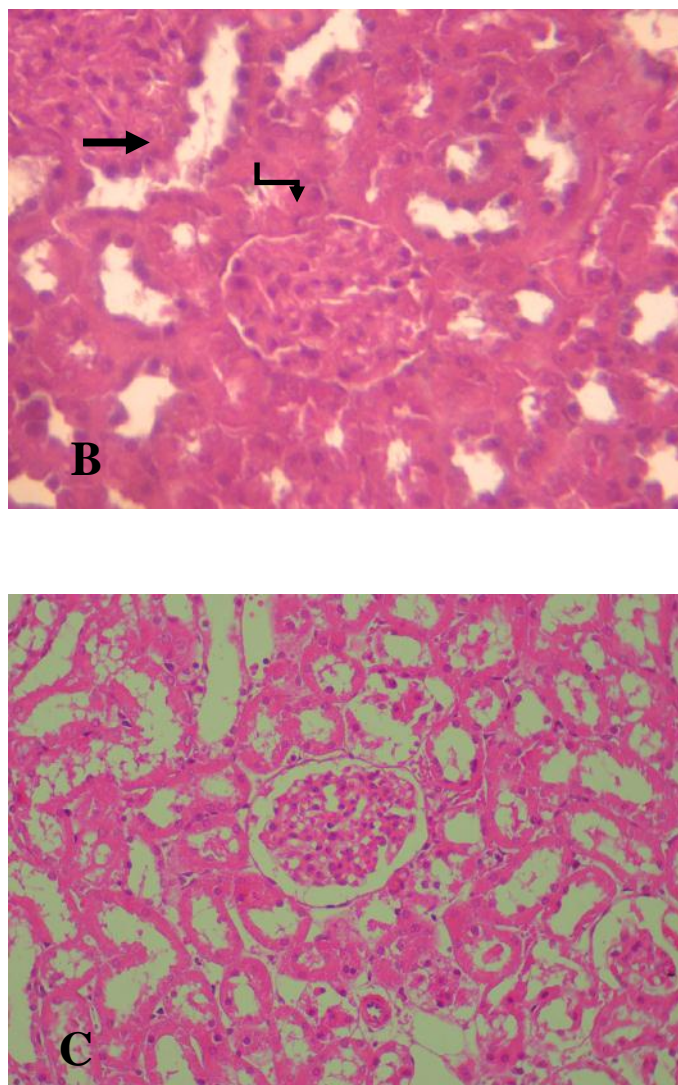






**Fig. 2:** Liver histological sections of the control (A), diabetic (B) and diabetic treated with *M. vulgare* (C). Original magnification was H.E (X 200). Arrows indicate: ( → ) Hepatic necrosis.





**Fig. 3:** Kidney histological sections of the control (A), diabetic (B) and diabetic treated with *M. vulgare* (C). Original magnification was H.E (X 200) for panels A and C, and H.E (X 400) for panel B. Arrows indicate: (→) Glomerular space reduction; (↘) Tubular Necrosis.

### DISCUSSION

In the present study, diabetes mellitus was induced in rats through alloxan injection that causes the destruction of  $\beta$ -cells of islets of Langerhans, as proposed by many authors<sup>24, 25</sup>. This effect was represented in the current study through the increase of blood glucose and a decrease of insulin levels in diabetic control rats. The elevated plasma glucose levels in diabetic rats were lowered through the administration of *M. vulgare* extract, which showed an elevated plasma insulin level compared to diabetic control rats. These findings are in agreement with that of Herrera-Arellano et al. (2004)<sup>5</sup> who reported that *M. vulgare*'s extract decreases the elevated

blood glucose and insulin levels in diabetic rats. Earlier phytochemical investigation of *M. vulgare* led to the characterization of several flavonoids that possess hypoglycemic property<sup>26</sup>. The richness of the aqueous extract of *M. vulgare* in flavonoids and verbascoside derivatives, known in the literature as antidiabetic agents, could be the origin of the observed effects. Some flavonoids have hypoglycemic properties because they improve altered glucose of the diabetic states<sup>27</sup>.

In addition, a significant increase in lipid peroxidation (LPO) contents, as measured by TBARS formation, was detected in the renal and hepatic tissue homogenate of diabetic rats.

These results are in line with several studies that have reported an increase in TBARS levels in kidney and liver of animal with experimental diabetes<sup>28, 29</sup>. Free radical-induced lipid peroxidation has been associated with a number of disease processes including diabetes mellitus<sup>30</sup>. The free radical produced may react with polyunsaturated fatty acids in cell membrane leading to lipid peroxidation. Increased lipid peroxidation impairs membrane functions by decreasing membrane fluidity and changing the activity of membrane-bound enzymes. As a consequence, it provokes damage in structural and functional integrity of hepatic and renal tissues. In addition, the increased lipid peroxidation under diabetic conditions could be due to increased oxidative stress in the cell as a result of the depletion of antioxidant defense systems<sup>31</sup>, like evidenced in our study by the decrease of enzymatic (SOD, CAT and GPx) and non-enzymatic (vit C, vit E and GSH) antioxidants activities in the renal and hepatic tissue homogenate of diabetic rats.

On the other hand, we observed that the treatment with MVAE (300 mg/kg) reduced the oxidative stress damage in the liver and kidney of *M. vulgare* treated diabetic rats. This significant improvement may in part be attributed to its antioxidant activities. *M. vulgare* leaves have been reported to be rich in flavonoid and phenolic compounds. The naturally occurring flavonoids and phenolics are believed to have the ideal chemical structure for scavenging free radicals<sup>32, 33</sup>. Particularly, marrubiin is considered the molecule responsible for the majority of the biological properties ascribed to *M. vulgare*. Apigenin and luteolin are definitely the most common flavonoids present in this plant extracts<sup>26</sup>. Therefore, strong antioxidant activity of *M. vulgare* could be attributed to its high total phenolics and flavonoids, suggesting their role in attenuating the renal and hepatic oxidative stress damage due to diabetes.

The histopathological examinations of renal and hepatic sections supported these biochemical results. In fact, diabetic liver revealed dilated sinusoids, hepatocytes with fatty change and mild periportal inflammatory cell infiltrate. Likewise, diabetic kidney shows fatty infiltration and mild inflammatory cell infiltrate. These damages might be due probably to the generation of reactive radicals and to subsequent lipid peroxidation induced by alloxan. While, the general morphology of hepatocyte, glomeruli and tubular lesions of the diabetic rats with the extract of *M. vulgare* was

much improved and seemed quite normal in appearance compared with that of diabetic rats. On the basis of the above evidences it is possible that the presence of flavonoids and phenolics are responsible for the observed antidiabetic activity.

We concluded that the hypoglycemic effect and the hepatorenal damage improvement of *M. vulgare* infusion on alloxan-diabetic rats may in part be due to its antioxidant activity. Further studies will be focused on a more rational use in traditional medicine of this plant.

## REFERENCES

1. Alwan A. Global status report on non communicable diseases. World Health Organization 2010. Geneva; 2011.
2. Ugochukwu NH, Babady NE, Cobourne MK and Gassett SR. The effect of Gongronema latifolium extracts on serum lipid profile and oxidative stress in hepatocytes of diabetic rats. J Biosci. 2003; 28:1-5.
3. Maritim AC, Sanders RA and Watkins JB. Diabetes, oxidative stress and antioxidants. J Biochem Mol Toxicol. 2003; 17: 24-38.
4. El-Bardai S, Lyoussi B, Wibo M and Morel N. Comparative Study of the antihypertensive activity of Marrubium vulgare and of the dihydropyridine calcium antagonist amlodipine in spontaneously hypertensive rat. Clin Exp Hypertens. 2004; 26: 465-474.
5. Herrera-Arellano A, Aguilar-Santamaria L, Garcia-Hernandez B and Nicasio-Torres P, Tortoriello J. Clinical trial of Cecropia obtusifolia and Marrubium vulgare leaf extracts on blood glucose and serum lipids in type 2 diabetics. Phytomedicine. 2004; 11: 561-566.
6. Schinella GR, Tournier HA, Prieto JM, Mordujovich de Buschiazco P and Rios JL. Antioxidant activity of anti-inflammatory plant extracts. Life Sciences. 2002; 70:1023-1033.
7. Sahpaz S, Garbacki N, Tits M and Bailleul F. Isolation and pharmacological activity of phenylpropanoid esters from Marrubium vulgare. J Ethnopharmacol. 2002; 79: 389-392.
8. Novaes AP, Rossi C, Poffo C, Pretti Júnior E, Oliveira AE, Schlemper V, Niero R, Cechinel-Filho V and Bürger C. Preliminary evaluation of the hypoglycemic effect of some Brazilian



- medicinal plants. *Therapie*. 2001; 56: 427-430.
9. Boudjelal A, Henchiri C, Siracusa L, Sari M and Ruberto G. Compositional analysis and in vivo anti-diabetic activity of wild Algerian *Marrubium vulgare* L. infusion. *Fitoterapia*. 2012; 83: 286-292.
  10. Mansour HA, Sayeda AL, Youssef MI and Sheweita SA. Biochemical study on the effects of some Egyptian herbs in alloxan-induced diabetics rats. *Toxicology*. 2002; 170: 221-228.
  11. Ghlissi Z, Hakim A, Mnif H, Makni AF, Zeghal K, Rebai T and Sahnoun Z. Evaluation of colistin nephrotoxicity administered at different doses in the rat model. *Ren Fail*. 2013; 35: 1130-1135.
  12. Makni M, Fetoui H, Gargouri NK, Garoui el M, Jaber H, Makni J, Boudawara T and Zeghal N. Flax and Pumpkin seeds mixture ameliorates diabetic nephropathy in rats. *Food Chem Toxicol*. 2010; 48: 2407-2412.
  13. Ghlissi Z, Hakim A, Sila A, Mnif H, Zeghal K, Rebai T, Bougatef A and Sahnoun Z. Evaluation of efficacy of natural astaxanthin and vitamin E in prevention of colistin-induced nephrotoxicity in the rat model. *Environ Toxicol Pharmacol*. 2014; 37: 960-966.
  14. Ben Khaled H, Ghlissi Z, Chtourou Y, Hakim A, Ktari N, Makni Ayadi F, Barkia A, Sahnoun Z and Nasri M. Effect of protein hydrolysates from sardinelle on the oxidative status and blood lipid profile of cholesterol-fed rats. *Food Res Inter*. 2012; 45: 60-68.
  15. Bradford M. A rapid and sensitive method for the quantification of microgram quantities of protein utilizing the principle of protein dyes binding. *Anal Biochem*. 1976; 72: 248-254.
  16. Draper HH and Hadley M. Malondialdehyde determination as index of lipid peroxidation. *Meth Enzymol*. 1990; 86: 421-431.
  17. Beauchamp C and Fridovich I. Superoxide dismutase: improved assays and an assay applicable to acrylamide gel. *Anal Biochem* 1971, 44: 276-287.
  18. Aebi H. Catalase in vitro. *Methods Enzymol*. 1984; 105: 121-126.
  19. Flohe L and Gunzler WA. Assays of glutathione peroxidase. *Methods in Enzymol*. 1984; 105: 114-121.
  20. Ellman GL. Tissue sulfhydryl groups. *Arch Biochem*. 1959; 82: 70-77.
  21. Jollow DJ, Mitchell JR, Zampaglione N and Gillete JR. Bromobenzene induced liver necrosis: protective role of glutathione and evidence for 3, 4-bromobenzeneoxide as the hepatotoxic intermediate. *Pharmacology*. 1974; 11: 151-69.
  22. Jacques-Silva MC, Nogueira CW, Broch LC, Flores EMM and Rocha JBT. Diphenyl diselenide and ascorbic changes deposition of selenium and ascorbic acid in liver and brain of mice. *Pharmacolol Toxicol*. 2001; 88: 119-125.
  23. Baker H, Frank O, De Angelis B and Feingod S. Plasma tocopherol in man at various times after ingesting free or acetylated tocopherol. *Nutr Rep Int*. 1980; 21: 531-536.
  24. Latsabidze I, Machavariani T, Gachechiladze I, Gvamichava T and Kavtashvili K. B-cells of rats pancreas and their supposed precursors during alloxan diabetes and after the action of Plaferon LB. *Georgian Med News*. 2011; 198: 40-45.
  25. Kasradze D, Tavartkiladze A, Kasradze M and Nozadze P. The study of melatonin protective activity on pancreatic  $\beta$ -cells under the condition of alloxan-induced diabetes during aging. *Georgian Med News*. 2010; 189: 56-63.
  26. Nawwar MAM, El-Mousallamy AMD, Barakat HH, Buddrus J and Linscheid M. Flavonoid lactates from leaves of *Marrubium vulgare*. *Phytochemistry*. 1989; 28: 3201-3206.
  27. Song Y, Manson JE, Buring JE, Howard D and Simin Liu S. Associations of dietary flavonoids with risk of type 2 diabetes, and markers of insulin resistance and systemic inflammation in women: a prospective study and cross-sectional analysis. *J Am Coll Nutr*. 2005; 24: 376-384.
  28. Yilmaz HR, Uz E, Yucel N, Altuntas I and Ozcelik N. Protective effect of caffeic acid phenethyl ester (CAPE) on lipid peroxidation and antioxidant enzymes in diabetic rat liver. *J Biochem Mol Toxicol*. 2004; 18: 234-238.
  29. Omara EA, Nada SA, Farrag AR, Sharaf WM and El-Toumy SA. Therapeutic effect of *Acacia nilotica* pods extract on streptozotocin induced diabetic

- nephropathy in rat. *Phytomedicine*. 2012; 19: 1059-1067.
30. Kumar G, Banu GS and Murugesan AG. Effect of *Helicteres isora* bark extracts on heart antioxidant status and lipid peroxidation in streptozotocin diabetic rats. *J Appl Biomed*. 2008; 6: 89-95.
31. Santini SA, Marra G and Giardina B. Defective antioxidant defenses and enhanced susceptibility to lipid peroxidation in uncomplicated IDDM. *Diabetes*. 1997; 46: 1853-518.
32. Pukalskas A, Venskutonis PR, Salido S, Waard Pd and van Beek TA. Isolation, identification and activity of natural antioxidants from horehound (*Marrubium vulgare L.*) cultivated in Lithuania. *Food Chem*. 2012; 130: 695-700.
33. Skerget M, Kotnik P, Hadolin M, Hras AR, Simoncic M and Knez Z. Phenols, proanthocyanidins, flavones and flavonols in some plant materials and their antioxidant activities. *Food Chem*. 2005; 89: 191-198.